

# PHOTODYNAMIC THERAPY IN AN EXPERIMENTAL MODEL OF ARTHRITIS INDUCED BY *PARACOCCIDIOIDES BRASILIENSIS*

## PHOTODYNAMIC THERAPY IN EXPERIMENTAL ARTHRITIS

### TERAPIA FOTODINÂMICA EM MODELO EXPERIMENTAL DE ARTRITE INDUZIDA POR *PARACOCCIDIOIDES BRASILIENSIS*

#### TERAPIA FOTODINÂMICA EM ARTRITE EXPERIMENTAL

Aniele Tomadon<sup>1</sup>, Eduardo Alexandre Loth<sup>1</sup>, Vanessa Cecatto<sup>1</sup>, José Henrique Firmino Ferreira dos Santos<sup>1</sup>, Mario José de Rezende<sup>1</sup>, Lucineia de Fátima Chasko Ribeiro<sup>2</sup>, Rose Meire Costa<sup>\*1</sup>

<sup>1</sup>Universidade Estadual do Oeste do Paraná, Centro de Ciências Biológicas e da Saúde, Cascavel, Paraná, Brasil.

<sup>2</sup>Universidade Estadual do Oeste do Paraná, Centro de Ciências Médicas e Farmacêuticas, Hospital Universitário do Oeste do Paraná, Cascavel, Paraná, Brasil.

\*Autor Correspondente: Rua Universitária, 2069 / Laboratório de Biologia Celular, JD Universitário, CEP 85819110 – Cascavel - PR [Brasil]. Telefone (45) 991010066. E-mail: rosecb@gmail.com

#### RESUMO

A terapia fotodinâmica (TFD) é um tratamento antifúngico que se destaca por não induzir resistência. O estudo objetivou avaliar os efeitos da TFD em modelo experimental de artrite articular induzida por *Paracoccidioides brasiliensis*. Para isto Ratos Wistar foram distribuídos em grupos e inoculados com *P. brasiliensis* ou PBS (controle) na articulação do joelho. Animais dos grupos TFD40 e TFD120 receberam tratamento com TFD 40 J/cm<sup>2</sup> e 120 J/cm<sup>2</sup>, respectivamente; o grupo MB, tratado com azul de metileno; e os grupos laser, L40 e L120, tratados com 40 J/cm<sup>2</sup> e 120 J/cm<sup>2</sup>, respectivamente. Foi observado que a formação de edema, titulação de anticorpos anti-Gp43 e o índice de artrite foram significativas nos grupos inoculados e menos evidentes nos grupos TFD40 e TFD120. Avaliação anatomopatológica do grupo TFD120 evidenciou melhora nos aspectos morfológicos da membrana sinovial, em comparação aos demais grupos inoculados. Conclui-se que TFD de 120 J/cm<sup>2</sup> reduz a artrite de forma mais efetiva, o que pode ter um potencial impacto no auxílio ao tratamento de *P. brasiliensis*.

**Descritores:** Paracoccidioidomicose; Articulações; Fotoquimioterapia; Joelho; Sinóvia.

#### ABSTRACT

Photodynamic therapy (PDT) is a fungal treatment that stands out because of its low toxicity and inability to induce microbial resistance. The study aimed to evaluate the effects of PDT in an experimental model of articular arthritis induced by *Paracoccidioides brasiliensis*. For this *Wistar* rats were distributed into groups and inoculated with *P. brasiliensis* or PBS (control) in the knee joint. After developing arthritis, the rats were treated. The PDT40 and PDT120 groups received treatment with PDT 40 J/cm<sup>2</sup> and 120 J/cm<sup>2</sup>; the MB group with methylene blue; and the L40 and L120, treated with 40 J / cm<sup>2</sup> and 120 J / It was observed that the formation of edema, titration of anti-Gp43 antibodies and arthritis index were significant in the inoculated and less evident groups in the PDT40 and PDT120. Anatomopathological evaluation of the PDT120 group showed the best synovial membrane morphology recovery. It is concluded that 120 J/cm<sup>2</sup> PDT is more effectively reduced arthritis than the other groups, which has the potential impact in the treatment of *P. brasiliensis* infections.

**Keywords:** Paracoccidioidomycosis; Joints; Photochemotherapy; Knee; Synovium.

## INTRODUCTION

Paracoccidioidomycosis (PCM) is mainly caused by inhaling the etiologic agent, *Paracoccidioides brasiliensis*, representing one of the most important systemic mycoses in Latin America, with an incidence of 80% of cases in Brazil, where it is considered a serious public health problem. It affects mainly men and rural workers between 30 and 59 years old, who are considered to be in their most productive life stage.<sup>(1,2)</sup>

The disease has two types of clinical presentations, the chronic (adult), especially affecting the lungs, and the acute-subacute (juvenile), with febrile lymphoproliferative syndrome being the main clinical manifestations.<sup>(2)</sup> The clinical presentations of PCM are dependent the immune response of the host, even as gender, age and ethnicity.<sup>(3)</sup> The osteoarticular involvement of PCM are variable, in the acute-subacute form of the disease estimated 20 to 40% of patients showing bone changes, and five to 10% showing articular changes,<sup>(4, 5)</sup> while in the chronic form, these osteoarticular events may present in up to 60% of PCM cases.<sup>(5)</sup> Articular manifestations of PCM include intense inflammation and loss of joint function. Several therapies have been used to control fungal mycosis, including drugs and potential use of photodynamic therapy (PDT), which stands out for its low cost, its centered action on the microorganism and its inability to confer microbial resistance.<sup>(6, 7, 8, 9)</sup> In that direction research with new and less invasive antifungal strategies as PDT could reduce the therapeutic time, the considerable morbidity and mortality caused by fungal infections<sup>(10)</sup> and increase the life quality of the patients. PDT involves the administration of a photosensitizer selectively delivered to the target microbial cells and activated by light source of an appropriate wavelength, in order to promote localized oxidative photodamage.<sup>(8)</sup> Liang et al.<sup>(8)</sup> stated that even if there was no clinical management for antifungal PDT, studies demonstrated that PDT was effective in the destruction of fungi *in vitro*. Wainwright et al. (2017)<sup>(11)</sup> discuss the need for research with these new therapeutic agents in the fight against drug-resistant infectious diseases, being a viable alternative to conventional drugs in many fields of application. Thus, the objective of the study was to evaluate the effect of PDT on the joints of Wistar rats with arthritis induced by *P. brasiliensis*.

## METHODS

The study was approved by the Research Ethics Committee involving animals from the Western State University of Parana (Unioeste), nº. 05/2013-CE, and the experimental animal maintenance complied with the guidelines of laboratory animal use prevailing in Brazil. Male 45-day-old *Wistar* rats (n = 42) were used for the *P. brasiliensis*-induced experimental model of arthritis,<sup>(11)</sup> which mimics human articular PCM.

The animals were distributed into seven groups of six animals each, one group control, injected intra-articularly with sterile PBS, and six infected groups with yeast *P. brasiliensis*. The yeast group received no treatment; the MB group received intra-articular methylene blue; the L40 and L120 groups were treated by laser at energy densities of 40 J/cm<sup>2</sup> and 120 J/cm<sup>2</sup>, respectively; the PDT40 and PDT120 groups were treated with PDT by laser at energy densities of 40 J/cm<sup>2</sup> and 120 J/cm<sup>2</sup> respectively.

Arthritis was induced with *P. brasiliensis* yeast (strain 18). Yeast samples were diluted in 1% PBS, at pH 7.2 to 7.4 and a concentration of 10<sup>5</sup>. Cells with >90% viability were used in the study, as determined by trypan blue staining.<sup>(12)</sup> To induce arthritis, 50 µL of a suspension containing 10<sup>5</sup> Pb18 yeast cells was injected into the animals' medial knee region with a 1-ml syringe and a 27-gauge needle.

After seven days of fungal inoculation, all groups except the yeast and control groups began treatment. The L40 and L120 groups were treated by laser at the energy densities of 40 J/cm<sup>2</sup> and 120 J/cm<sup>2</sup>, respectively. The laser used was the Ibramed (Amparo, SP, Brazil) GaAlAs (660 nm, 30 mW), which was applied daily and punctually to the knee that received the inoculum. The laser groups were created to analyze the isolated irradiation effect for its action against the microorganisms.<sup>(13)</sup>

The MB group, which was treated with the methylene blue photosensitizer, was used to verify the dye's isolated effect for its bactericidal characteristics.<sup>(14)</sup> On the first day of treatment, this group was injected with 50 µL of methylene blue (diluted in sterile 1% PBS) in the arthritic joint, and the subsequent dose was induced after 48 h.

Animals in the PDT40 and PDT120 groups were treated with PDT on the eighth day, which consisted of injecting the knee with 50 µL of methylene blue

(diluted in 1% sterile PBS) intra-articularly, with the subsequent dose being injected 48 hours later. After the first shot with the photosensitizer, the 40 and 120 J/cm<sup>2</sup> daily treatments with the GaAlAs laser (specifications above) were applied punctually.

On the 11<sup>th</sup> day, at the end of the treatments, blood was collected from the animals for ELISA (*enzyme-linked immunosorbent assay*) analyses. Each animal's right knee joint was fixed in formalin solution and decalcified with trichloroacetic acid, and the samples were processed for paraffin embedding. Histological sections were stained with hematoxylin and eosin to analyze the general tissue morphology and silver using the Grocott method.<sup>(15)</sup>

Edema formation was evaluated by measuring the lateral diameter of the extended right knee joint in millimeters using a Western digital pachymeter. This was measured before inoculating with *P. brasiliensis* and remeasured each day of the study.<sup>(12)</sup>

The arthritis was evaluated using the scale of arthritis, per Hansch et al.,<sup>(16)</sup> punctuating from 0.5 to 3 for each item based on the presence and intensity of the morphological changes, such as synovial membrane hyperplasia, synovial tissue cellular infiltration, pannus formation, and cartilage destruction.

ELISA was performed per Ramos et al.<sup>(17)</sup> to evaluate the anti-gp43 antibody titration. Briefly, 96-well plates were sensitized with purified gp43 antigen using secondary antibody (anti-IgG peroxidase, Sigma-Aldrich®). The assays were performed in triplicate and read by an absorbance microplate reader at 492 nm.

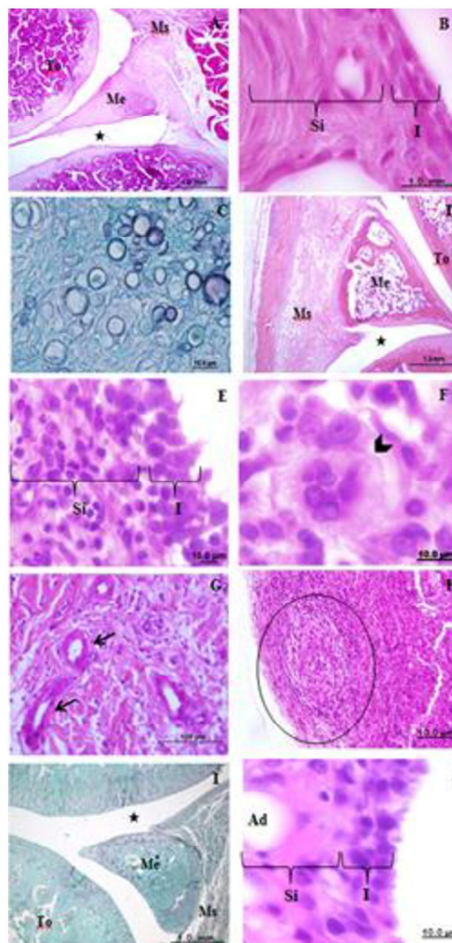
For the statistical analysis, numerical variables were analyzed inferentially using two-sided, unpaired Student's t-tests for between-group comparisons to evaluate the treatments. ANOVA and Tukey's multiple comparison test were used to compare the histopathological variables. The significance level was set at 5%, with the  $\alpha$  value set at  $p < 0.05$ . Statistical analysis was performed using GraphPad Prism® software, version 3.0 for Windows XP for the Microsoft Office® platform.

## RESULTS

Anatomopathological analysis of the *P. brasiliensis*-infected groups revealed joint involvement in the intimal and subintimal layers of the synovial membrane region (Figure 1). In the control group,

no changes were observed in the tissue morphology (Figure 1A and 1B).

**Figure 1:** Photomicrographs of the right posterior limb joint in male *Wistar* rats, sagittal section. A: panoramic view of the control group joint (without infection) at 4x magnification; B: control group synovial membrane at 1000x magnification; C: several fungi in the synovial membrane at 1000x magnification; D: panoramic view of the yeast group joint infected with *P. brasiliensis* and untreated at 4x magnification; E: yeast group synovial membrane at 1000x magnification; F: multinucleated cell in the synovial membrane at 1000x magnification (+); G: angiogenesis present in the yeast group at 1000x magnification; H: immature granuloma; I: panoramic view of the PDT120 group articulation treated with PDT at 120 J/cm<sup>2</sup> at 4x magnification; J: synovial membrane of the PDT group at 120 J/cm<sup>2</sup>. Intima (I), subintimal (Si), adipocytes (Ad), giant multinucleated cell (arrowhead), blood vessels (arrows), immature granuloma (circle). Hematoxylin and eosin staining in photomicrographs, A, C, E, F, G, H, I, and Grocott staining in C and I.



*P. brasiliensis* presence in the infected joints was confirmed by the Grocott staining method (Figure 1C).

Anatomopathological analysis of the yeast group revealed classical signs of articular PCM present in the synovial membrane region (Figure 1D): increasing cellularity, lymphocyte and plasmocyte infiltration, diffuse inflammatory infiltrate, pannus formation with multilayer formation in the synovial membrane from loss of epithelioid arrangement (Figure 1E), presence of giant multinucleated cells (Figure 1F), angiogenesis (Figure 1G), granulomatous formation with unorganized granulomas (Figure 1H) and edema (Table 1).

In groups L40, L120 and MB, these signals remained present, but more attenuated. In the PDT40 group, the changes were concentrated in the perimeniscal

region of the subintimal layer; however, in the PDT120 group (Figure 1I) cellularity was decreased compared with the yeast group, with more adipocytes and lower edema formation (Figure 1J) than the other treated groups.

Anatomopathological analysis showed more attenuated signs of chronic inflammation in the PDT 120 J/cm<sup>2</sup> treatment.

Evaluating the edema showed an increased articular volume in the yeast group knees (p-value = 0.0001). In the other treated groups (L40, L120, MB, PDT120 and PDT40), no significant increase was observed. At the end of the experiment, the PDT groups showed the lowest swelling rates (PDT40 and PDT120 groups with p-value=0.8359 and p-value = 0.7167, respectively), as shown in Table 1.

Table 1: Presentation of the medium diameter and lateral diameter (mm) of the animals' posterior right knee joints at the beginning and end of the experiment.

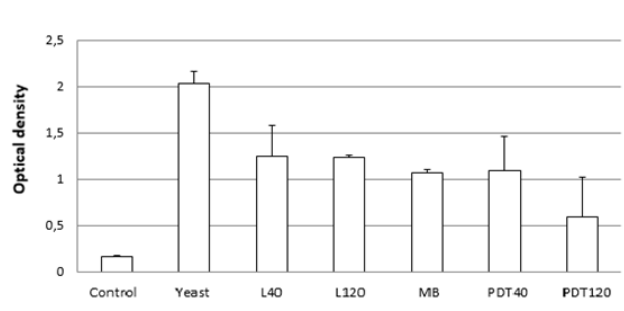
GROUPS	Pre-inoculation	8 <sup>th</sup> day	11 <sup>th</sup> day	Difference**	P value
Control	10,28 ± 0,17	10,32 ± 0,20	10,48 ± 0,30	1,95%	0,6261
Yeast	10,47 ± 1,57	13,10 ± 1,16	14,70 ± 1,26	40,40%	0,0001*
L40	11,12 ± 0,49	12,33 ± 0,72	12,04 ± 0,49	8,87%	0,0625
L120	11,28 ± 0,44	11,53 ± 0,52	11,80 ± 0,44	4,61%	0,1563
MB	11,13 ± 1,06	11,26 ± 0,36	11,43 ± 1,06	2,70%	0,2970
PDT40	11,83 ± 0,85	10,89 ± 0,83	11,92 ± 0,85	0,76%	0,8359
PDT120	12,27 ± 0,77	12,43 ± 0,40	12,16 ± 0,77	1,87%	0,7167

\*\*Difference between pre-inoculation and 11<sup>th</sup> day.

The arthritis index per Hansch et al.<sup>(16)</sup> showed that the most intense inflammation was achieved in the yeast, MB and L40 groups (p-value <0.05). The PDT120 group presented the lowest arthritis score (mean index of 0.75 points), but with no statistically significant difference compared with the other treated groups.

The titration analysis of the *P. brasiliensis* anti-gp43 antibodies indicated greater specific antibody production in the yeast group (p-value= 0.001). No statistically significant differences were observed in the other groups when the averages were compared (Figure 2).

Figure 2: Optical density reading of the anti-gp43 antibody concentration. Optical density reading of the anti-gp43 antibody concentration in the groups' serological samples (n=42); control group without infection and treatment; yeast group, infected and untreated; L40 treated by laser at 40 J/cm<sup>2</sup>; L120 treated by laser at 120 J/cm<sup>2</sup>; MB treated with methylene blue; PDT40 treated by laser at 40 J/cm<sup>2</sup> combined with methylene blue; PDT120 treated by laser at 120 J/cm<sup>2</sup> combined with methylene blue; P, significance level p <0.05;\*, Significant value compared with the other groups by ANOVA and Tukey's multiple comparison test.



## DISCUSSION

This was a pioneer study of the use of PDT to aid in the treatment of arthritis induced by *P. brasiliensis*, in which specific antifungal drug therapy is used<sup>2</sup>.

Joint changes caused by *P. brasiliensis* in the experimental arthritis model showed anatomopathological aspects of fungal infection with primary involvement of the synovial membrane region in its intimal and subintimal layers, as described by Loth et al.<sup>(11)</sup>.

Articular edema formation in the fungal-infected groups, except PDT40 and PDT120, has also been reported by other authors including Loth et al.<sup>(11)</sup> and Amanai et al.,<sup>(18)</sup> who used *Candida albicans* in an osteoarthritis model in rats. Edema caused by the pathogen was reduced and partially normal tissue aspects were observed in the joint's synovial membrane region after applying PDT to treat the arthritis caused by *P. brasiliensis*. These results were the most significant after using the 120 J/cm<sup>2</sup> dosage.

Tanaka et al.<sup>(19)</sup> induced murine experimental arthritis with methicillin-resistant *S. aureus* and found a bactericidal effect with improved inflammation using the low PDT dosage of 20 J/cm<sup>2</sup>. A bibliographic research in databases evaluate efficacy and safety of PDT<sup>(8)</sup> for skin mycoses and investigators have shown that PDT inactivates *Trichophyton rubrum* cells by apoptosis, the most common causative agent of dermatophytosis. Others dermatophytes, including *T. mentagrophytes*, *T. tonsurans*, *Microsporum cookei*, *M. gypseum*, and *Epidermophyton floccosum* can also controlled by the therapy.<sup>(9)</sup>

PDT is also effective for yeast and reduced *Candida albicans* growth in 40% or more and their viability by 50%.<sup>(20)</sup>

The PDT120 group had a lower rate of arthritis than the other treatments. Based on a review by Lins et al.,<sup>(21)</sup> laser therapy likely promotes biostimulation by accelerating injured tissue repair. Therefore, the anti-gp43 antibody analysis showed less titration, demonstrating the reduced immunological response, likely due to a decreased fungal load after the therapy. PDT induces the production of harmful radicals, the reactive species of oxygen and nitrogen that kill fungus cells<sup>(22, 23)</sup> by apoptosis, necrosis, or autophagy.<sup>(24)</sup> Moreover, Shikanai-Yassuda et al.<sup>(2)</sup> showed a positive

correlation between specific antibody expression and disease severity.

After analyzing the anti-gp43 antibody titration, the data showed greater production in the yeast group, with higher values than those presented by Loth et al.<sup>(11)</sup> on day 15 of the experiment, even when using purified gp43 antigen (a glycoprotein weighing 43 kilodaltons) and using a highly specific test for this antigen. Reaction may have occurred between immunoglobulin isotypes, likely IgM.<sup>(11)</sup>

The treatment of paracoccidioidomycosis available today is drug based, many of them are nephrotoxicity, myocardial toxicity and myelotoxicity, and should be used with caution.<sup>(25)</sup> Furthermore, studies have shown paracoccidioides resistance and sometimes a failure of the drug treatment.<sup>(26)</sup> Alternatives treatments like PDT could represents a useful and less invasive strategy to control disease, and now the data of this study suggest that PDT has a great promise for combating *P. brasiliensis*.

## CONCLUSION

For *P. brasiliensis* established intra-articularly, PDT treatment at 120 J/cm<sup>2</sup> improved the tissue morphology and reduced the joint volume.

## ACKNOWLEDGMENTS

We would like to thank the laboratory partners and the financial support of CNPq - National Council for Scientific and Technological Development (process 443952/2014-0), which allowed the development of this study.

## REFERENCES

1. Coutinho ZF, Silva D, Lazera M, Petri V, Oliveira RM, Sabroza PC, et al. Paracoccidioidomycosis mortality in Brazil (1980-1995). *Cad Saude Publica*. 2002;18(5):1441-54.
2. Shikanai-Yasuda MA, Mendes RP, Colombo AL, Telles FQ, Kono A, Paniago AMM, et al. II Consenso Brasileiro em Paracoccidioidomicose – 2017. *Epidemiol Serv Saude*, Brasília, 27(núm. esp.):e0500001, 2018.
3. Bellissimo-Rodrigues F, Bollela VR, Da Fonseca BA, Martinez R. Endemic paracoccidioidomycosis: relationship between clinical presentation and patients' demographic features. *Med Mycol*. 2013;51(3):313-8.

4. Scheinberg MA, Cohen M, Abdalla RJ, Guidule J. Artroscopia na blastomicose articular do joelho: um relato de caso. *Rev Bras Ortop.* 1994;29(8):577-8.
5. Rocha FF, Campos MG. Monoartrite como manifestação de Paracoccidioomicose. *Rev Panam Infectol.* 2007;9:31-3.
6. Martinez R. Atualização no uso de agentes antifúngicos. *J Bras Pneumol.* 2006;32(5):449-60.
7. Scorzoni L, de Paula e Silva AC, Marcos CM, Assato PA, de Melo WC, de Oliveira HC, Costa-Orlandi CB, Mendes-Giannini MJ, Fusco-Almeida AM. Antifungal Therapy: New Advances in the Understanding and Treatment of Mycosis. *Front Microbiol.* 2017;8:36. Review.
8. Liang YI, Lu LM, Chen Y, Lin YK. Photodynamic therapy as an antifungal treatment (Review). *Exp Ther Med.* 2016;12(1):23-7.
9. Baltazar L, Ray A, Santos D, Cisalpino P, Friedman A, Nosanchuk J. Antimicrobial photodynamic therapy: An effective alternative approach to control fungal infections. *Front Microbiol.* 2015;6(202):1-11. Review.
10. Wainwright M, Maisch T, Nonell S, Plaetzer K, Almeida A, Tegos GP, Hamblin M R. Photoantimicrobials—are we afraid of the light? *Lancet Infect Dis.* 2017;17(2):e49–e55.
11. Loth EA, Biazim SK, Santos JH, Puccia R, Brancalhão RC, Chasco LF, et al. Dose response effect of *Paracoccidioides brasiliensis* in an experimental model of arthritis. *Rev Inst Med Trop Sao Paulo.* 2014;56:259-64.
12. Strober W. Trypan blue exclusion test of cell viability. *Curr Protoc Immuno.* 2015;111(A3.B):1-3.
13. Mayer-Biscanin M, Mravak-Stipetic M, Ierolimov V. Effect of low-level laser therapy on candida albicans growth in patients with denture stomatitis. *Photomed laser Surg.* 2005;23:328-32.
14. Calzavara PGP, Venturini M, Sala R. A comprehensive overview of photodynamic therapy in the treatment of superficial fungal infections of the skin. *J Photochem Photobiol B.* 2005;78:1-6.
15. Grocott RG. A stain for fungi in tissue sections and smears using Gomori's methenamine–silver nitrate technic. *Am J Clin Pathol.* 1955;25:975–9.
16. Hansch A, Frey O, Gajda M, Susanna G, Boettcher J, Bräuer R, et al. Photodynamic treatment as a novel approach in the therapy of arthritic joints. *Lasers Surg Med.* 2008;40:265–72.
17. Ramos SP, Sano A, Ono MA, Camargo ZP, Estevão D, Miyaji M, et al. Antigenuria and antigenaemia in experimental murine paracoccidiooidomycosis. *Med Mycol.* 2005;43:631–6.
18. Amanai T, Nakamura Y, Aoki S, Mataga I. Micro-CT analysis of experimental *Candida* osteoarthritis in rats. *Mycopathologia.* 2008;166:133–41.
19. Tanaka M, Kinoshita M, Yoshihara Y, Shinomiya, N, Seki, S, Nemoto, K, et al. Photodynamic Therapy Using Intra-Articular Photofrin for Murine MRSA Arthritis: Biphasic Light Dose Response for Neutrophil-Mediated Antibacterial Effect. *Lasers Surg Med.* 2011;43:221-9.
20. Giroldo LM, Felipe MP, De Oliveira MA, Munin E, Alves LP, Costa MS. Photodynamic antimicrobial chemotherapy (PACT) with methylene blue increases membrane permeability in *Candida albicans*. *Lasers Med Sci.* 2009;24:109-12.
21. Lins RD, Lucena KC, Granville-Garcia AF, Dantas EM, Catão MH, Carvalho Neto LG. Efeitos bioestimulantes do laser de baixa potência no processo de reparo. *An Dermatol.* 2010;85:849-55.
22. Dai T, Fuchs BB, Coleman JJ, Prates RA, Astrakas C, St Denis TG, et al. Concepts and principles of photodynamic therapy as an alternative antifungal discovery platform. *Front Microbiol.* 2012;3:120.
23. Krausz A, Friedman AJ. News, views, & reviews: antimicrobial photodynamic therapy: applications beyond skin cancer. *J Drugs Dermatol.* 2014;13:624-6.
24. Mroz P, Yaroslavsky A, Kharkwal GB, Hamblin MR. Cell death pathways in photodynamic therapy of cancer. *Cancers (Basel).* 2011;3:2516-39.
25. Ferreira MS. Paracoccidiooidomycosis. *Paediatric Respiratory Reviews.* 2009;10(4):161-5.
26. Shikanai-Yasuda MA. Paracoccidiooidomycosis treatment. *Rev Inst Med Trop.* 2015; 57(19):31-7.